



**PATIENT PRESENTING CLINICAL SIGNS**

Loki Koo History: Stage 1 kidney disease.

**SPECIES** Physical Examination: N/A.

Canine Urinalysis: N/A.

CBC: N/A.

**BREED** Serum Biochemistry: Elevated liver enzyme activity and bilirubin. Positive *Leptospira* snap with history of vaccinations.

Labrador Mix Radiographic Findings: N/A.

**SEX**

MN

**AGE**

6 years

**WEIGHT**

89 #

**ULTRASONOGRAPHIC EXAMINATION OF THE ABDOMEN**

**Urinary System**

Empty urinary bladder with a normal thickness and appearance of the wall. Multiple small uroliths (up to 0.8 cm). Visible urinary catheter.

Normal trigone, proximal urethra (0.7 cm), and iliac blood vessels.

Normal iliac lymph nodes. Ureters not visualized.

Normal renal size (left 7.3 cm, right 6.9 cm), echogenic appearance, cortico-medullary differentiation, pelvis and capsule. Faint cortical mineralization in the right kidney.

**Reproductive System**

Small hypoechogenic prostate (1.6 cm).

**Adrenal Glands**

Normal shape, echogenic appearance, size, and position. Left 0.58/0.46 cm, right 0.55/0.64 cm.

**Spleen**

Normal size (1.7 cm) and echogenic appearance. Smooth homogenous parenchyma, regular curvilinear capsule, and normal vasculature. No evidence of inflammatory, neoplastic, infarction, or infiltrative changes noted.

**Liver**

Normal size with increased echogenic appearance, some loss of portal markings, and regular curvilinear capsule. No nodules or masses evident. Distended gall bladder containing adherent and non-adherent hyperechogenic sediment arranged in a stellate pattern. Thickened and hyperechogenic appearance of the gall bladder wall. Normal bile duct.

**INTERPRETED BY**

Remo Lobetti, BVSc,  
MMedVet (Med), PhD, Dipl.  
ECVIM

**IMAGING PERFORMED BY**

Sonya Myers, DVM

**HOSPITAL NAME**

Oviedo Veterinary Care and  
Emergency

**REFERRING VET**

Dr King

**INVOICE**

303145

**DATE**

7/26/22


**PATIENT** *Gastrointestinal*

Loki Koo

**SPECIES**

Canine

**BREED**

Labrador Mix

**SEX**

MN

**AGE**

6 years

Normal appearance of the duodenum, small intestine, ileo-cecal junction, and colon with no loss of layering, normal wall thickness (duodenum 0.39 cm, jejunum 0.37 cm, colon 0.3 cm) and peristaltic activity, and no distension of the lumen. Segmental thickening of the stomach (up to 0.86 cm) with no loss of layering or distension of the lumen.

**Pancreas**

Normal size (2.2 cm), echogenic appearance, and curvilinear capsule. Normal echogenic appearance of the mesentery and fat surrounding the pancreas.

**Free Abdomen**

Mesenteric lymphadenomegaly (0.5 x 2.4 cm) with normal shape and echogenic appearance.

No ascites

Hyperechogenic appearance of the mesentery around the gall bladder and ileo-cecal junction.

**ULTRASONOGRAPHIC FINDINGS**
**WEIGHT**

89 #

Primary Findings:

- Hepatopathy.
- Mucocele.
- Gastritis.
- Mesenteric inflammation.
- Mesenteric lymphadenomegaly.

**INTERPRETED BY**

Remo Lobetti, BVSc,  
MMedVet (Med), PhD, Dipl.  
ECVIM

Secondary Findings:

- Uroliths.

**IMAGING PERFORMED BY**

Sonya Myers, DVM

**HOSPITAL NAME**

Oviedo Veterinary Care and  
Emergency

**REFERRING VET**

Dr King

**INTERPRETATION OF THE FINDINGS & FURTHER RECOMMENDATIONS**

Etiologies for the hepatopathy would be secondary to the gall bladder, reactive, vacuolar, metabolic, Leptospirosis, and chronic hepatitis, with infiltrative neoplasia, a far less likely differential diagnosis.

Etiologies for the gastritis would be non-specific (viral, bacterial, protozoal, helminths, toxins, dietary indiscretion), *Helicobacter* gastritis, ulcerative disease, inflammatory bowel disease, and dietary hypersensitivity.

**INVOICE**

303145

The mesenteric inflammation and lymphadenomegaly can be ascribed as reactive secondary to the gall bladder and gastritis.

Further assessment would be urine and fecal analyses, *Leptospira* titers/PCR, and possibly FNA cytology of the liver and gastroscopy with biopsies.

**DATE**

7/26/22

Specific therapy would be cholecystectomy as there appears to be abdominal inflammatory changes; this would also allow biopsy of the liver, stomach and lymph nodes; and cystotomy to remove the uroliths. Symptomatic management would be ursodiol.



**PATIENT IMAGES**

Loki Koo **Liver**

**SPECIES**

Canine

**BREED**

Labrador Mix

**SEX**

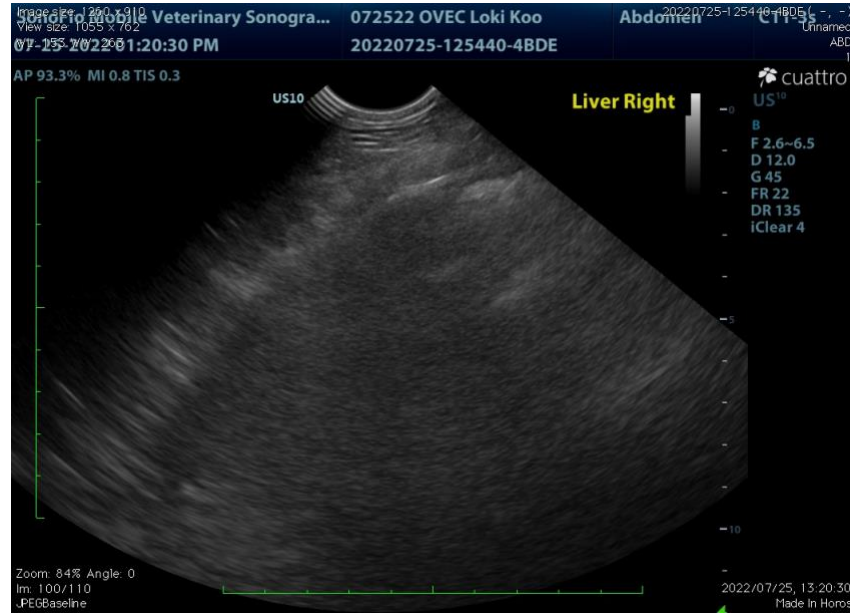MN

**AGE**

6 years

**WEIGHT**

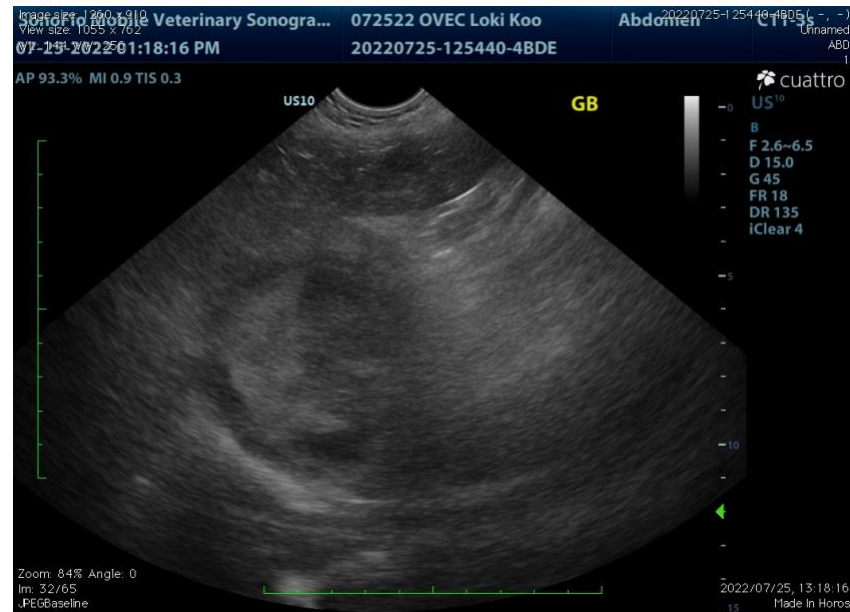89 #



**INTERPRETED BY**

Remo Lobetti, BVSc,  
 MMedVet (Med), PhD, Dipl.  
 ECVIM

**Gall bladder**



**IMAGING PERFORMED BY**

Sonya Myers, DVM

**HOSPITAL NAME**

Oviedo Veterinary Care and  
 Emergency

**REFERRING VET**

Dr King

**INVOICE**

303145

**DATE**

7/26/22



**PATIENT**      **Stomach**

Loki Koo

**SPECIES**

Canine

**BREED**

Labrador Mix

**SEX**

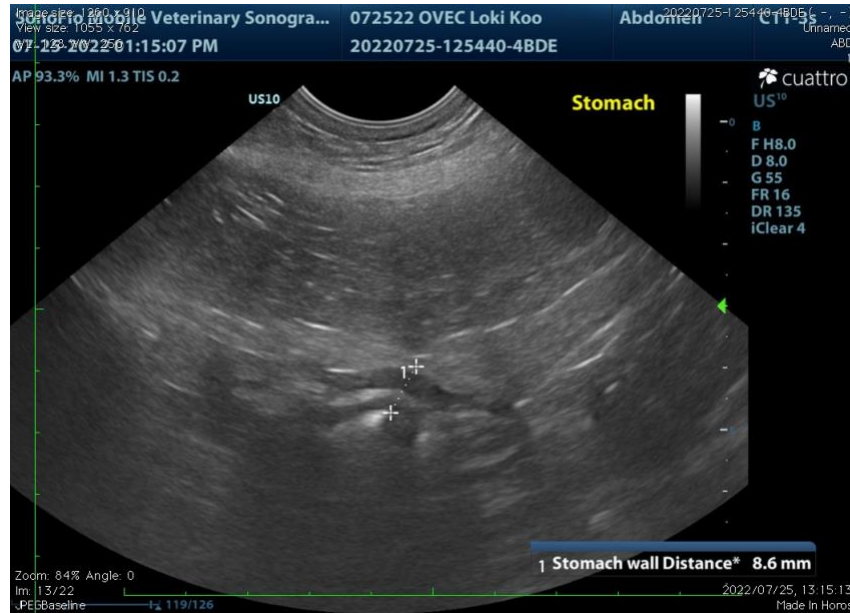MN

**AGE**

6 years

**WEIGHT**

89 #



**Small intestine/mesentery**

**INTERPRETED BY**

Remo Lobetti, BVSc,  
 MMedVet (Med), PhD, Dipl.  
 ECVIM

**IMAGING PERFORMED BY**

Sonya Myers, DVM

**HOSPITAL NAME**

Oviedo Veterinary Care and  
 Emergency

**REFERRING VET**

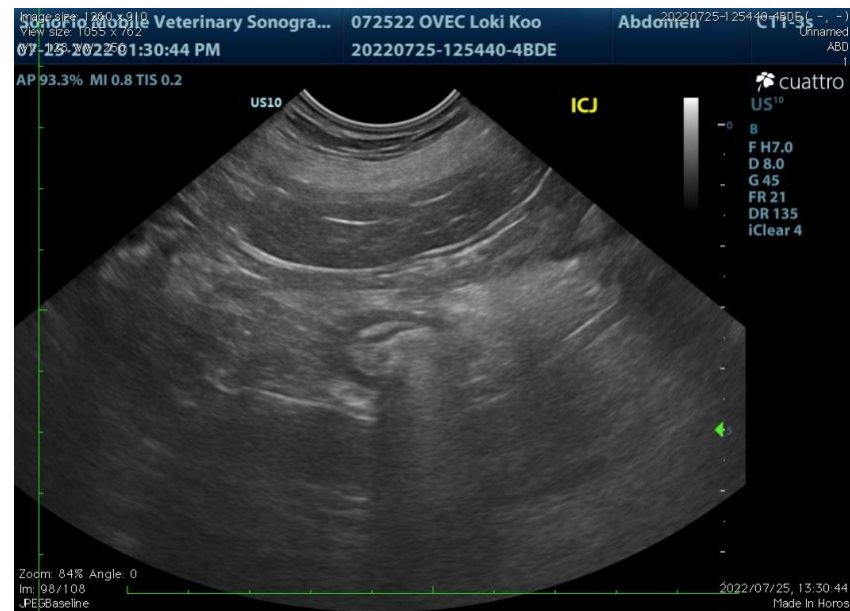Dr King

**INVOICE**

303145

**DATE**

7/26/22





**PATIENT** Urinary bladder

Loki Koo

**SPECIES**

Canine

**BREED**

Labrador Mix

**SEX**

MN

**AGE**

6 years

**WEIGHT**

89 #

**INTERPRETED BY**

Remo Lobetti, BVSc,  
 MMedVet (Med), PhD, Dipl. ECVIM

**IMAGING PERFORMED BY**

Sonya Myers, DVM

**HOSPITAL NAME**

Oviedo Veterinary Care and  
 Emergency

**REFERRING VET**

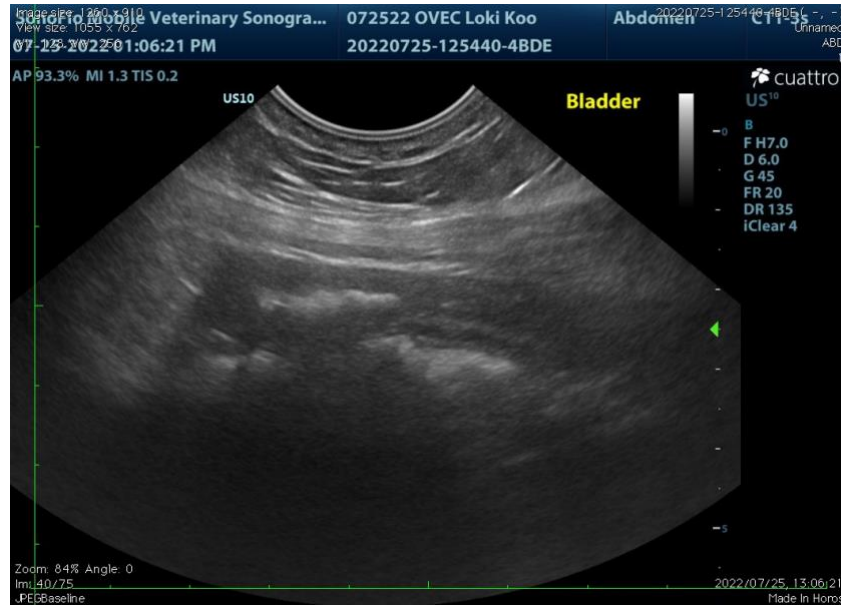
Dr King

**INVOICE**

303145

**DATE**

7/26/22



The information and recommendations provided are based on the images presented by the referring veterinarian. No evaluation can be communicated regarding pathology that was not visible in the image/video clips provided.

Thank you for this referral. If the clinical or image interpretation does not parallel your findings or if I can be of any further assistance, please contact me.

**Remo Lobetti, BVSc, MMedVet (Med), PhD, Dipl. ECVIM (Internal Medicine)**  
[rlobetti@mweb.co.za](mailto:rlobetti@mweb.co.za)